

Letters to Editor

The tunneled perforator flap

We read with great interest the article on the 'throw over perforator flap', by Bajantri *et al.*^[1] When no appropriate perforators were found adjacent to the defect on the same side of the leg, the authors had used perforators from the other side of the leg. The authors had then incised the normal intervening skin, and had 'thrown over' the flap to cover the defect. They have termed this technique based on the mode of transfer.

We would like to differ from the authors on two things:

1. The technique of incising the normal intervening skin between the perforator and the defect has been previously described by Bhattacharya *et al.*^[2] In their article on the retrograde skeletonised perforator flaps, they state that in more distally-located defects the intervening normal tissue is incised and raised as two skin flaps, to accommodate the vascular pedicle and the adjacent part of the flap.
2. The authors have harvested a perforator flap on a non-adjacent perforator, not in continuity with the defect, from the other side of the leg. We believe that a perforator on the other side of the leg does not make it non-adjacent. Although not in continuity with the defect, it is still adjacent; only on the opposite side.

The concept of the use of perforators from the opposite side of the defect from the non-traumatic zone, proposed by Bajantri *et al.*,^[1] is laudable, and we have used this technique after the authors described it, with good results.

We have had the opportunity to manage two patients of groin defects, where an anterolateral thigh perforator flap was used to cover the defect. The flap was harvested from an area that was not in continuity with the defect, and was then tunneled below the intervening normal skin to cover the defect. [Figures 1, 2]. Muscle flaps are regularly tunneled beneath the intervening tissue to cover the defect at many centers including ours. To the best of our knowledge and literature search, use of the tunneling technique in perforator flaps is not yet documented. We

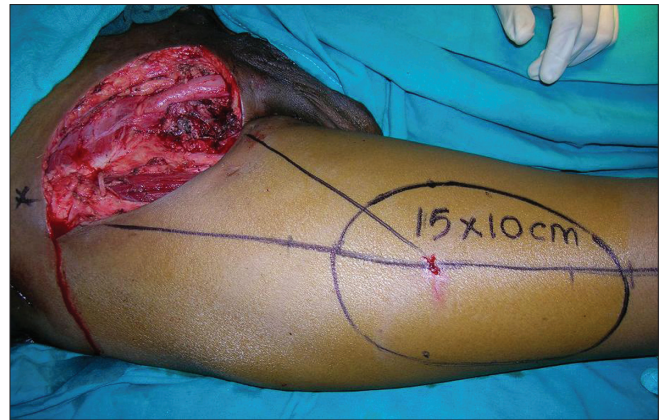


Figure 1: Cutaneous markings of the Anterolateral thigh perforator flap

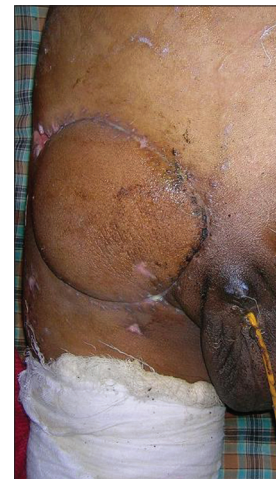

Figure 2: Well settled ALT perforator flap tunneled beneath intervening normal skin

have termed it as the 'tunneled' perforator flap based on the technique of transfer.

In case of perforator flaps, due care must be taken when using this technique, because the perforators can get compressed with the minimal of pressures, leading to flap congestion or ischaemia.

An adequate-sized tunnel is of paramount importance when using this technique for perforator flaps. It is, therefore, indicated only in those areas where there is sufficient laxity in the tissues to create adequate-sized tunnels.

An advantage of this technique is that additional scars are avoided.

The intervening skin bridge is already elevated and if of adequate size functions as a delayed flap to be used as a life boat in case the first flap fails.

Nikhil Panse, Parag Sahasrabudhe

B.J Medical College and Sassoon hospital, Pune, India

Address for correspondence:

Dr. Nikhil Panse, Assistant Professor in Plastic Surgery,
Vimal Niwas, Sudarshan Society, Near Model colony post office,
Shivajinagar, Pune 16, India.
E-mail: nikhil.panse@rediffmail.com

REFERENCES

1. Bajantri B, Sabapathy SR, Burgess TM. The 'throw over flap': A modification of the propeller flap for reconstruction of non-adjacent soft tissue defects. Indian J Plast Surg 2011;44:525-6.
2. Bhattacharya V, Reddy GR, Goyal S, Kumar U. Skeletonised retrograde distal perforator island fasciocutaneous flaps for leg and foot defects. J Plastic Reconstr Aesthet Surg 2007;60:892-7.

Access this article online	
Quick Response Code: 	Website: www.ijps.org
	DOI: 10.4103/0970-0358.96597